

Research Article

The Overview of the Effectiveness of Infrared on the Healing Rate of Incision and Burn Wounds in Male White Rats

Fuad Ama, Rini Purbowati & Emillia Devi Dwi Rianti*

Department of Biomedical, Faculty of Medicine, Universitas Wijaya Kusuma Surabaya, Jawa Timur, Indonesia

*Corresponding Author: emillia@uwks.ac.id

ABSTRACT

Infrared rays have low energy and their use does not cause toxic effects on the environment, so that infrared rays can balance and activate cells in the body, thin the blood, break down water molecules, and inhibit bacteria or fungi. Inhibition of bacterial or fungal growth in skin wounds that are often experienced and cause damage to epithelial tissue. The purpose of the study provides an overview of the effectiveness of infrared on the healing rate of incision wounds and burns in Wistar rats. The method with an experiment with a completely randomized design method, the sample used was 48 male white rats with 24 with incision wounds and 24 with burns. The results of the incision wound on the 12th day showed that there was a reduction in the length of the wound at P1 (0.1 cm), P2 (0.1 cm) and P3 (0.2 cm) so that with a wound length of 0.1 means healing has occurred. Burns on the 12th day there was a decrease in the diameter of the burn wound both at P1 = P2 = P3 = 0.3 cm. Conclusion The use of infrared therapy in the healing process of incision wounds and burns on days 9-12. Infrared wavelength 940 nm as near infrared produces heat, so the healing process is less than 14 days.

Keywords: Infrared; Healing; Incision Wound; Burn Wound

1. INTRODUCTION

Currently, infrared rays are widely used as healing therapy. Infrared rays cannot be seen and are electromagnetic waves, with a frequency of 300 GHz – 40,000 GHz, so infrared rays are produced from processes within molecules and in hot objects. Infrared waves are electromagnetic radiation which is longer than visible light and shorter than microwave radiation. Infrared rays are formed from hot objects that experience atomic and molecular vibrations which produce heat waves (Rianti,2021).

Infrared rays have a longer wavelength than visible light, so infrared rays are used as a therapy for pain complaints resulting from inflammation (Untari, 2023). According to Afifah (2019), in her research, she explained that infrared rays have low energy and their use does not cause toxic effects on the environment, so infrared rays can balance and activate cells in the body, thin the blood, break down water molecules, and inhibit bacteria or fungi. In this study, researchers used infrared light as a therapy for wound healing.

Inhibition of bacterial or fungal growth in wounds on the skin which are often experienced and result in damage to epithelial tissue. Because the skin has an important role in protecting the body from foreign objects, injured skin can result in disruption of the normal anatomical structure of the skin. Wounds experience cellular disorders that lose anatomical tissue continuity, so there is a response from the body to heal the wound (Wilantari,2019). Riskesdas (2013) explains that the prevalence of injuries in Indonesia has increased every year, in 2013 there was an increase of 47.7%. Residents experienced the three highest levels of injuries, namely abrasions or bruises (70.9%), sprains (27.5%), lacerations (23.2%) (Ministry of Health, 2013). Wardani (2021) explains that wounds are damage to body tissue due to factors that interfere with the body's protection. Understanding incised or cut wounds is a type of wound that manifests as linear tears in the skin and tissue.

An incision wound is a wound that is damaged by body tissues due to a sharp object, in the healing process with repair of tissue injury from several phases, namely the inflammatory phase, the proliferasl phase and the remodeling phase. If the wound has a chronic condition, it must be treated quickly because it will be contaminated with bacteria so that infection can occur (Wilantari, et al., 2019). Not only cuts or incisions that can cause infection, one of the wounds, namely burns, can also become infected. Because burns are damaged or lose tissue caused by heat sources. Efforts that can be made for burn

therapy are the provision of therapy to prevent secondary inflammation, aiming to prevent infection, help the formation of collagen and help the remnants of the epithelium develop so that the wound can close quickly (Balqis, 2014). Kurnianto (2017) explained that burns that experience infection are a serious problem because they can result in delayed epidermal maturation and the formation of scar nets and infections are the cause of morbidity and mortality. The research conducted aims to provide an overview of the effectiveness of infrared on the healing rate of incision wounds and burns in male white rats.

2. RESEARCH METHOD

The type of research used in this research is an experiment with a completely randomized design method. The tools used are calipers, nails, Bunsen, scalpel number 10, handsocon, mask, and infrared box with a wavelength of 940 nm. The research object used male white rats (*Rattus novergicus*) with a body weight of ± 250 -300 grams and aged 2-2.5 months. The number of male white mice used was 24, according to Federer's formula (Maryanto and Fatimah, 2004). The samples were divided into 2 groups, namely the control group and the treatment group with treatment groups P1, P2 and P3 and each consisting of 6 white mice. There were 24 incision wounds and burns each, so the total number of white mice was 48. Incision wounds by giving a wound 2 cm long and 0.2 mm deep, and for burns using a nail with a head with a diameter of 1.20 cm. The treatment group was divided into three groups, namely wounds given an infrared distance of 7 cm (P1), an infrared distance of 16 cm (P2), and an infrared distance of 25 cm (P3) for 20 minutes. Independent variables: Infrared distance 7 cm, infrared distance 16 cm, and infrared distance 25 cm with a time of 20 minutes. Dependent/bound variable: healing of incision wounds and burns in male white rats. Control variables: wound length, wound depth, diameter and method of infrared exposure.

3. RESULTS AND DISCUSSION

3.1 Results

The research was carried out in the experimental animal laboratory at Wijaya Kusuma University, Surabaya with experimental samples of male white rats (*Rattus novergicus*) with a body weight of ± 250 -300 grams and aged 2-2.5 months. The number of samples from each treatment of incised wounds and burns was 24 individuals. Treat incised wounds on white mice by giving a wound with a scalpel number 10 on the back of the white mouse, and the length of the wound is 2 cm long and 0.2 mm deep. To treat rats, they were given burns by giving wounds to their backs from a nail with a head with a diameter of 1.20 cm and burning it over Bunsen and then placing it directly on the back of the experimental animal. Treatment of experimental animals before incisions or burns were carried out, experimental animals were given ketamine which aims to reduce pain in male white mice.

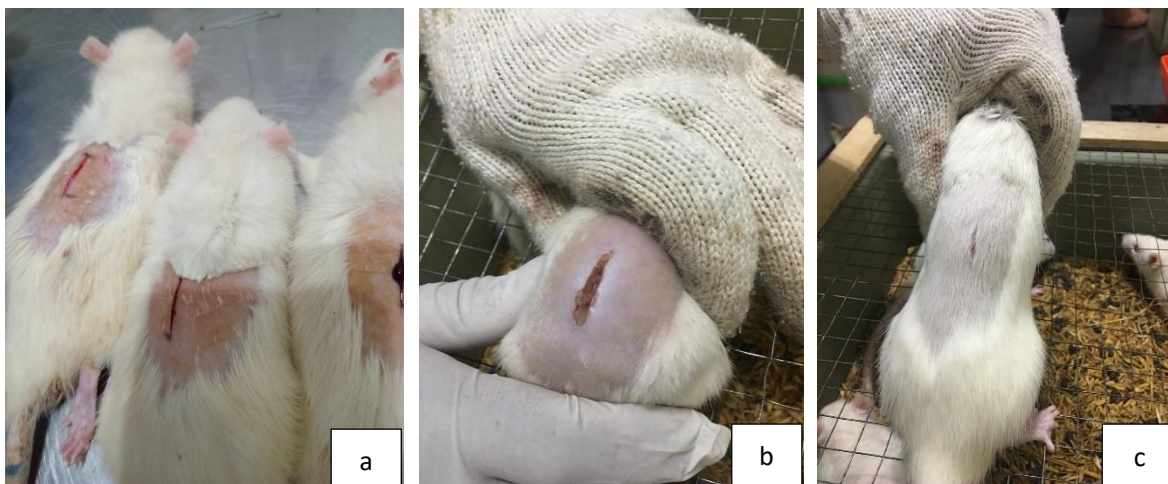


Figure 1. Results of an incision wound on a male white rat, with a wound on the skin of the white rat with a wound length of 2 cm and a depth of 0.2 mm (a), an incision wound treated with infrared therapy with a therapy time of 20 minutes (b), an incision wound that has healed and hair has grown to cover the wound (c)

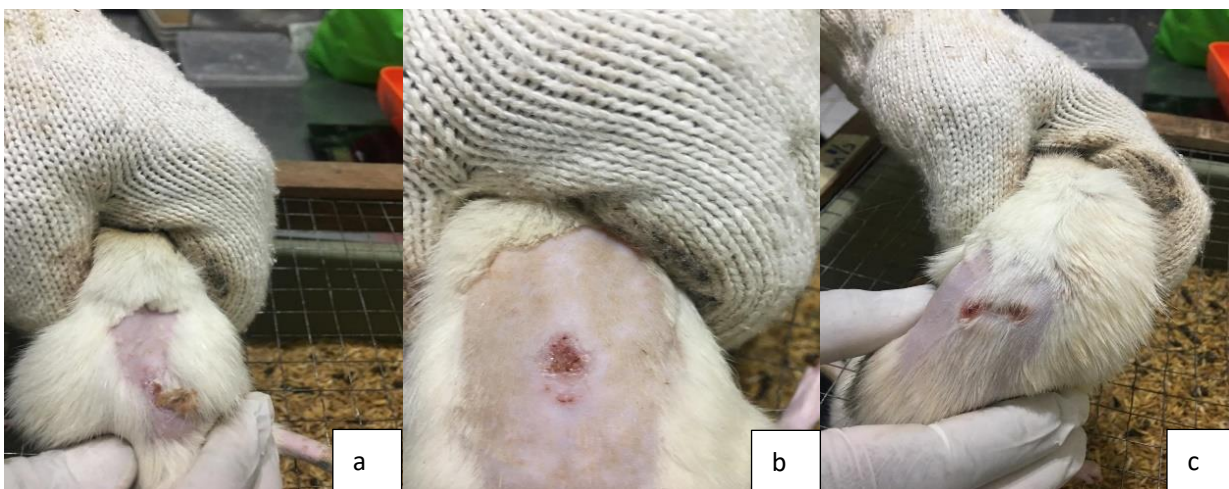


Figure 2. Results of the description of burn wounds on male white rats, skin wounds with burns with a diameter of 1.20 cm (a), skin burns given infrared therapy (b), burn wounds healing (c)

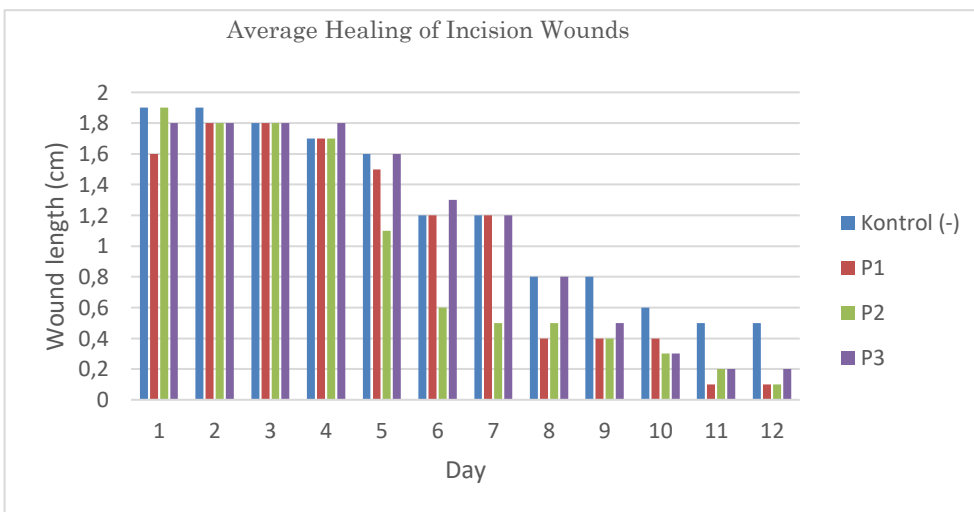


Figure 3. Data results from the average wound length in incisional wounds

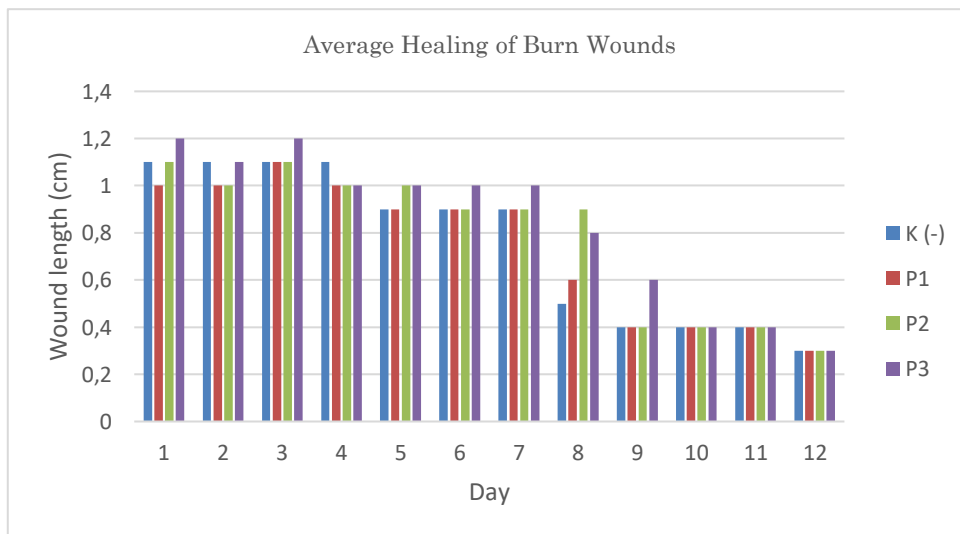


Figure 4. Data results from the average diameter of the wound in burns

3.2 Discussion

A wound is a condition where the integrity of the skin occurs when it experiences friction, due to exposure to temperature, chemicals and radiation. The causes of injuries vary, resulting in open or closed wounds. The occurrence of wounds on the skin will interfere with the protective function of the skin and will result in the body's life being threatened. A wound is defined as a condition where there is a disruption in continuity that results in damage to the tissue (Asyifa et al., 2023). Research carried out on male white rats involved incised wounds and burns, and wound healing was carried out using infrared therapy. Infrared therapy uses a wavelength of 940 nm with a time of 20 minutes and varying distances of 7 cm, 16 cm and 25 cm. Currently, the use of infrared for therapy is widely used for health. Infrared therapy aims to reduce pain, based on Kaye et al., (2010) and Putra et al., (2017) who explain that the use of infrared therapy is used to significantly treat the musculoskeletal system thereby reducing pain. The heat generated from infrared therapy can be absorbed by the skin, so in this study by utilizing the heat from infrared therapy it is hoped that it can heal incised wounds and burns in white mice.

Figure 1 shown that white mice treated with incision wounds, shown in pictures a and b, with skin tissue that was given an incision wound and then given infrared therapy (b), showed redness at the edges of the injured skin tissue, reduced thickness and length of the wound. decreasing. The condition of the incisional wound by administering infrared therapy reduces the existing scar tissue, so the healing process is faster. Primasari (2020) explains that in the natural healing process there is scar tissue. The results of the research show that scar tissue does not form, healing occurs (c) and hair grows around the skin tissue. The white rat fur that had covered the wound remained white, clean and thick. The clinical picture of young male mice has yellowish white fur, smooth, clean and thick fur (Rosmarwati, 2022). Burns are a problem that must be considered, because they can result in morbidity and complications from the wounds caused. Wounds result from heat and will cause damage to the skin and redness and peeling wounds. Research on male white rats with burns is shown in Figure 2. The results of the burns on the skin show the formation of yellowish red and dry wounds (a), then the burns were treated with infrared to speed up healing and the skin tissue showed reddish dry wounds (b), Healing occurs in the skin tissue which experiences a reduction in the width of the wound diameter and around the wound the skin grows hair (c). Based on the cause and degree of burns, burns are divided into two, namely degrees I and II. The general appearance of burns is redness of the skin, blistering, peeling, swelling, the skin looks white to charred (Kaihena, 2021).

Figure 3 shown the duration of therapeutic healing in male white mice for incision wounds which explains that on day 4 there was a reduction in the length of the wound and the results showed an average of 1.7 cm on P1 and P2. Day 5 showed a reduction in wound length on P2 (1.1 cm) as well as on day 7 (0.5 cm). The wound length results are shown in the graph for P1 on day 8 (0.4 cm), for P3 on day 9 (0.5 cm) and day 10 (0.3). Day 12 shows that there is a reduction in wound length at P1 (0.1 cm), P2 (0.1 cm) and P3 (0.2 cm), so a wound length of 0.1 means healing is occurring.

Figure 4 shows the results obtained that the healing of burn wounds on P1, P2 and P3 with a reduction in the width of the wound diameter seen on day 9 shows P1 = 0.4 cm, P2 = 0.4 cm and P3 = 0.6 cm. On day 12, there was a reduction in the diameter of the burn wound at P1=P2=P3 = 0.3 cm. Healing of incised wounds and burns resulted in a decrease in the length and diameter of the wounds occurring on the 9th and 12th days. A wound condition is a state of damage to body tissue due to tearing of muscles, connective tissue and skin due to tears, scratches and burns. Research that looks at the healing of incised wounds and burns given infrared therapy. Infrared is radiation that produces heat. Gunawan's (2019) research on the healing process of incisional wounds in mice from experimental animals on day 1. 5th and 15th after incision. According to Kurnianto (2017), burns in the healing process can heal in less than 14-21 days. The use of infrared therapy shows that the healing process in incised wounds and burns occurs on days 9-12. Infrared which has a wavelength of 940 nm as near infrared produces heat. So, the healing process using infrared therapy on incised wounds and burns can heal in less than 14 days. According to Sukmawati (2023), the wound healing process is influenced by temperature. So in this study the wound healing process was due to infrared therapy producing heat thereby speeding up the healing process.

4. CONCLUSION

Use of infrared therapy in the healing process for incised wounds and burns on days 9-12. Infrared wavelength 940 nm as near infrared produces heat, so the healing process takes less than 14 days.

ACKNOWLEDGEMENTS

Thanks to Dr. Dorta Simamora as head of the experimental animal laboratory at Wijaya Kusuma University, Surabaya.

REFERENCES

- Author, F. & Author, S. (2018). Please Use APA Style for References. Name of the Journal, 12(3), 456-789. <https://doi.org/10.1234/56789>
- Afifah IS., Hasan., Yuniarti N., Lubis B. (2019). Efektifitas Variasi Waktu Kontak Sinar Inframerah Terhadap Penurunan Angka Kuman Pada Alat Makan. Jurnal Riset Kesehatan Poltekkes Depkes Bandung Vol. 11. No.2
- Asyifa TN., Mustofa A., Ismunandar H., Utama WT. (2023). Cara-cara Untuk Mempercepat Penyembuhan Luka. Medula. Volume 12. Nomor 4:659-666
- Balqis U., Rasmaidar., Marwiyah. (2014). Histopathological Finding of Burn Healing Using Ambarella Leaf (*Spondias dulcis* F.) and Coconut Oil on Rats (*Rattus norvegicus*). Jurnal Medika Veterinaria Vol. 8 No. 1, 30-35
- Gunawan, SA. I K Berata, IW Wirata. (2019). Histopatologi Kulit pada Kesembuhan Luka Insisi Tikus Putih Pasca Pemberian Extracellular Matrix (ECM) yang Berasal dari Vesica Urinaria Babi (Histopatology Of Skin In Recovery Incision Wound In Rat Post Giving Extracellular Matrix (Ecm) From Pork's Vesica Urinaria). Indonesia Medicus Veterinus Mei 2019 8(3): 313-324
- IGA AK Wardani., NN W Udayani., IGA AD Suari. (2021). Effectivity of *Gliricidia Sepium* (Jacq.) Walp. Folium Ethyl Acetate Extract Ointment on Wound Healing in Male White Rats. Jurnal Ilmiah Medicamento • Vol. 7 No. 2 • tahun 2021. 102-107 <https://medicamento.unmas.ac.id>
- Kaihena M, Welmince T. Luarwan . (2021). Penyembuhan Luka Bakar Tikus *Rattus norvegicus* Pasca Diberi Gel Ekstrak Etanol Daun Cengkeh (*Syzygium aromaticum* L.) (Healing Burns of *Rattus norvegicus* After Being Given Ethanol Extract Gel Clove Leaf (*Syzygium aromaticum* L.)). Jurnal Kalwedo Sains (KASA). Maret 2021 ISSN: 2722-6964 (online) Volume 2, Nomor 1, 34-40
- Kaye, A. D., Baluch, A., & Scott, J. T. (2010). Pain management in the elderly population: A review. Ochsner Journal, 10(3), 179–187.
- Kurnianto S., Kusnanto., Padoli. (2017). Penyembuhan Luka Bakar Pada Tikus Putih Dengan Menggunakan Ekstrak Daun Pegagan (*Centella Asiatica*) 25% Dan Ekstrak Daun Petai Cina (*Leucaena Leucocephala*) 30%. Jurnal Ilmiah Kesehatan, Vol. 10, No. 2, Agustus 2017, Hal 250-255
- Kurnianto S., Kusnanto., Padoli. (2017). Penyembuhan Luka Bakar Pada Tikus Putih Dengan Menggunakan Ekstrak Daun Pegagan (*Centella Asiatica*) 25% Dan Ekstrak Daun Petai Cina (*Leucaena Leucocephala*) 30%. Jurnal Ilmiah Kesehatan, Vol. 10, No. 2, Agustus 2017, Hal 250-255
- Maryanto dan Fatimah. 2004. Metodologi Penelitian. Mataram: Yayasan Cerdas press
- Primasari ,M.(2020). Pencegahan dan Tatalaksana Jaringan Parut Abnormal. Cermin Dunia Kedokteran-283. vol. 47 no. 2, 87-91
- Putra, A., Rahmalita, A., Tarra, Y., Prihananti, D. H., Hutama, S. H., & Sa'Diyah, N. A. C. (2017). The effect of mesenchymal stem cells on the endothelial cells of diabetic mice. In Advances in Biomolecular Medicine - Proceedings of the 4th BIBMC (Bandung International Biomolecular Medicine Conference) 2016 and the 2nd ACMM (ASEAN Congress on Medical Biotechnology and Molecular Biosciences) 2016.
- Rachmanita RT., Primarizky H., Fikri F., Setiawan B., Agustono B., Saputro AL. (2019). Effectivity Of Bitter Leaf Extract (*Vernonia Amygdalina*) Topically On Collagen Density On Incision Wound Healing In Rats (*Rattus norvegicus*). Jurnal Medik Veteriner DOI: 10.20473/jmv.vol2.iss1.2019.36-41 April 2019, Vol.2 No.1 : 36-41 online pada <https://e-journal.unair.ac.id/JMV>
- Rianti EDD., Tania POA., Listyawati AF. (2021). Pengaruh Paparan Sinar Inframerah Terhadap Pertumbuhan Koloni *Staphylococcus Aureus* Dan *Escherichia Coli* Dengan Indikator Jumlah Koloni. Prosiding Semnas Biologi ke-9 Tahun 2021 FMIPA Universitas Negeri Semarang
- Rosmarwati, E. Ellistasari EY., Kusumawardani A. (2022). Gambaran Klinis Dan Histopatologi Kulit Tikus Sprague-

Dawley Pada Kelompok Tikus Muda, Tua, Dan Tikus Model Tua Induksi Dgalaktosa. *Herb-Medicine Journal*. Volume 5, Nomor 3, 1-8 ISSN: 2620-567X

Sumiati., Tridiyawati F.(2022).Pengaruh Inframerah Terhadap Penyembuhan Luka Perineum Pada Ibu Primigravida Di Klinik Amalda(*Infrared Effect on Perineum Wound Healing in Primigravidal Women At Amalda Clinic*), *Jurnal Ilmiah Keperawatan (Scientific Journal of Nursing)* Edisi Khusus, Vol 8, No. 3. 78-82

Untari I., Prasojo I., Sarifah S., Nugroho E. (2023). Sinar Infra Merah dengan Otomatis Kontrol Suhu (SIMOKS) untuk Meningkatkan Kenyamanan Terapi pada Lansia. *JRST (Jurnal Riset Sains dan Teknologi)* - Vol.7 (1) 2023 - (45-50)

Wilantari, P. D., Santika, A. A. G. J., Buana, K. D. M., Samirana, P. O., Sudimartini, L. M., dan Semadi, W. J, (2019). Aktivitas Penyembuhan Luka Insisi dari Salep Daun Binahong (*Anredera scandens (L.) Moq.*). *Jurnal Farmasi Udayana*, 8.